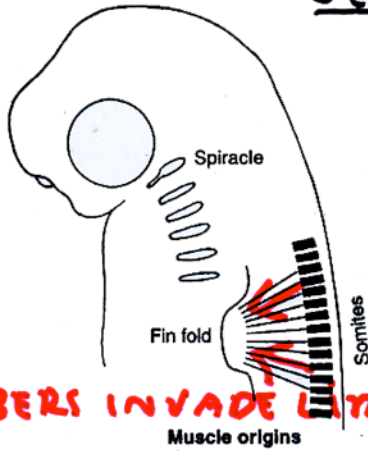


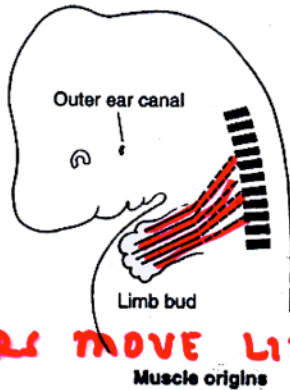
"SECONDARY" APPENDICULAR MUSCLE 1



FIBERS INVADE LIMB
EARLY DEVELOPMENT

- 1) MYOTOME OF SOMITE ORIGINATES DORSALLY
- 2) MYOTOME MIGRATES VENTRALLY INTO LIMB
- 3) SECONDARILY IN APPENDAGE

a. ORIGIN ON AXIAL SKELETON




FIBERS MOVE LIMB
LATE DEVELOPMENT

- 4) SECONDARY EXTRINSIC MUSCLE
- a. BEGAN DEVELOPMENT OUTSIDE LIMB = SECONDARY
- b. ORIGIN OUTSIDE LIMB = EXTRINSIC

"PRIMARY" APPENDICULAR MUSCLE

- 1) MUSCLE PRECURSORS IN LIMB (NOT SOMITE)



- 2) PRIMARY IN APPENDAGE

a. BEGAN DEVELOPMENT INSIDE LIMB = PRIMARY