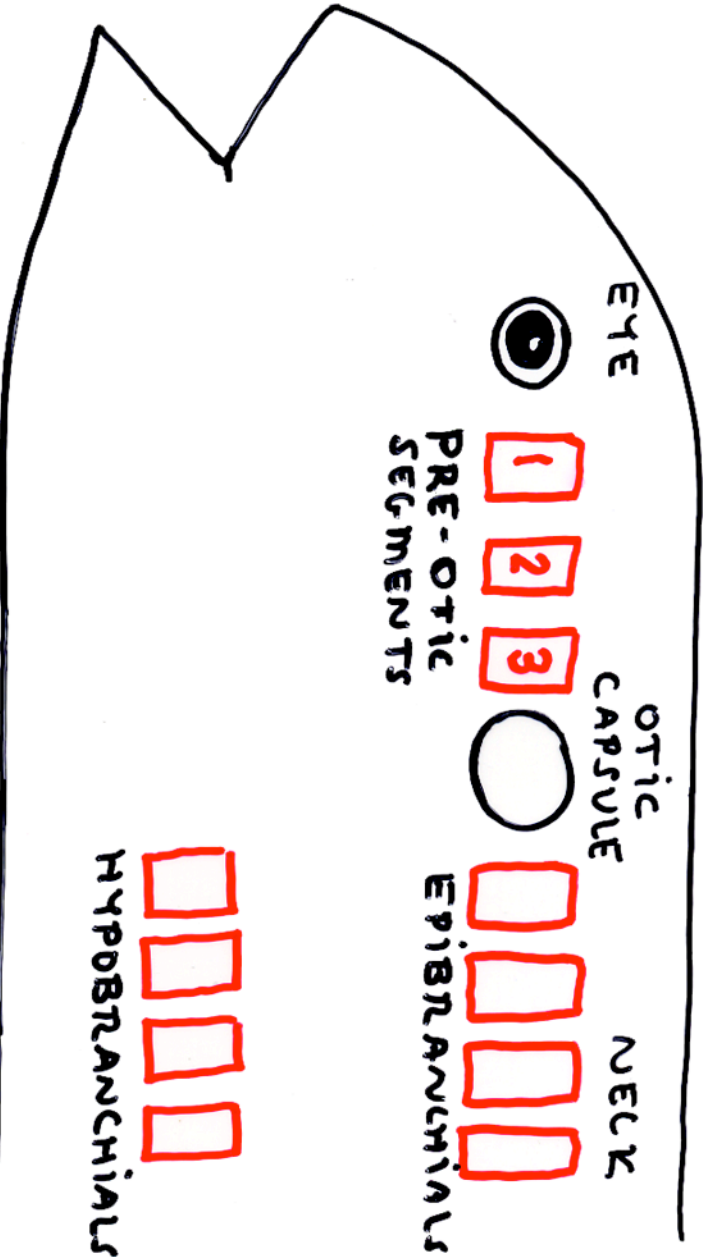


Myotome Segments in Head Region

EPIBRANCHIALS
MOVE NECK



PRE-OTIC SEGMENTS

1 → 4 muscles } MOVE EYE
 2 → 1 " " }
 3 → 1 " " }

HYPOBRANCHIAL

ANCESTRAL FUNCTION
 MOVE TAIL
DERIVED FUNCTION
 MOVE TONGUE VIA HYOID