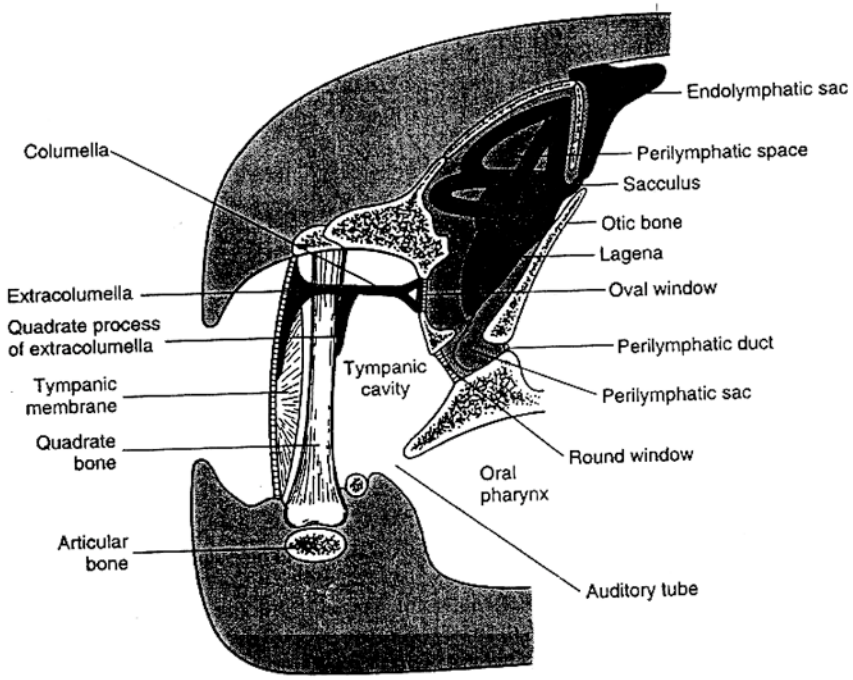
Endolymphatic sac
Columella
Perilymphatic space
Sacculus
Otic bone
Lagena
Extracolumella
Oval window
Quadrate process
of extracolumella
Perilymphatic duct
Tympanic
cavity
Tympanic
membrane
Perilymphatic sac
Quadrate
bone
Round window
Oral
pharynx
Articular
bone
Auditory tube

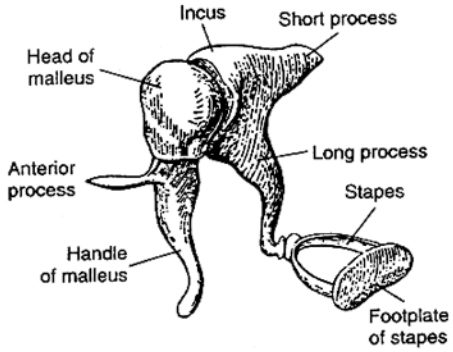
Incus
Short process
Head of
malleus
Long process
Anterior
process
Stapes
Handle
of malleus
Footplate
of stapes